Original Article

Eur J Breast Health 2024; 20(1): 57-63
DOI: 10.4274/ejbh.galenos.2023.2023-11-6

Potential Usefulness a Coronal View using an Automated Breast Ultrasound System in Detecting Breast Lesions

Megumi Suzuki[1], Ryohei Nakayama[2], Kiyoshi Namba[1], Hiroyuki Kawami[1], Mayumi Nara[1], Seigo Nakamura[3]

[1]Center for Breast Diseases and Breast Cancer, Hokuto Hospital, Hokkaido, Japan
[2]Department of Electronic and Computer Engineering, Ritsumeikan University, Shiga, Japan
[3]Breast Center, Showa University Hospital, Tokyo, Japan

ABSTRACT

Objective: An automated breast ultrasound system (ABUS) combined with screening mammography has increased cancer detection rates; however, supplemental ABUS use has increased recall rates. In this study, we aimed to identify an accurate and efficient method of ABUS interpretation and evaluate the potential usefulness of its coronal view versus the conventional transverse view.

Materials and Methods: This retrospective observer study included comprised 114 ABUS cases (40 normal, 35 benign, 39 malignant). Ten physicians from multiple institutions interpreted the anonymized coronal and transverse views independently. The observers scored their confidence in the lesion detection for each case using a continuous scale and recorded reading times for each coronal and transverse view interpretation. Free-response receiver operating characteristic analysis was employed to compare detection accuracies between views; a paired t-test was used to compare the average reading times.

Results: Detection accuracy did not differ significantly between the coronal and transverse views (figure of merit=0.740 and 0.745, respectively; p = 0.72). However, the average reading time for the coronal view was significantly shorter than that for the transverse view (149.7 *vs.* 200.3 seconds per case, p = 0.003).

Conclusion: The coronal view obtained with the ABUS was useful for interpretation and associated with significantly shorter reading times compared with the conventional transverse view while maintaining breast lesion detection accuracy.

Keywords: Automated breast ultrasound; breast cancer screening; breast ultrasonography; retrospective observational study

Cite this article as: Suzuki M, Nakayama R, Namba K, Kawami H, Nara M, Nakamura S. Potential Usefulness a Coronal View using an Automated Breast Ultrasound System in Detecting Breast Lesions. Eur J Breast Health 2024; 20(1): 57-63

Key Points

- The coronal view obtained from an automated breast ultrasound system was useful for results interpretation.
- This coronal view in the automated breast ultrasound system was associated with significantly shorter reading times compared with the conventional transverse view while maintaining breast lesion detection accuracy.
- Interpretation accuracy may be increased by interpreting a mass with retraction in the coronal view and focusing on hypoechoic non-mass lesions and lesions located behind the nipples in the transverse view.

Introduction

Mammography is the standard imaging method for breast cancer screening and allows for the early detection of breast cancers, resulting in reduced breast cancer mortality (1). However, the sensitivity of mammography depends on breast density, as tumor visibility is significantly reduced in dense breasts. The overall sensitivity of mammography is 72% (2). However, it is only 30–50% in women with dense breasts, either heterogeneously dense or with extremely dense parenchyma (2, 3). Approximately 55.4% of women aged <50 years and 29.3% of women aged >50 years have dense breasts with parenchymal density >50% (4).

An automated breast ultrasound system (ABUS) (5) was initially proposed as a screening modality, and adjunct use of the ABUS with mammography has increased cancer detection rates, especially in women with dense breasts (as defined by the American College of Radiology's Breast Imaging Reporting and Data System) (6, 7). The SomoInsight study, a trial reported by Brem et al. (7), revealed the detection of an additional 1.9 cancers per 1,000 women

Corresponding Author:
Megumi Suzuki; megumi.breast@gmail.com

Received: 04.12.2023
Accepted: 19.12.2023
Available Online Date: 27.12.2024

with dense breasts when an ABUS was combined with screening mammography.

The ABUS was developed to overcome the limitations of operator dependency, poor standardization, and reproducibility of handheld ultrasound (HHUS), with identical diagnostic accuracy to that of HHUS (8-10). Furthermore, ABUS showed similar efficacy for cancer detection with less benign findings compared with HHUS, suggesting that ABUS can potentially decrease the incidence of false positives (11). Use of an ABUS allows for the uncoupling of acquisition and interpretation, with the advantage of double-reading, objective comparison with previous examinations, and re-evaluation of stored images, even after the acquisition. Chou et al. (12) reported that an ABUS provided reproducible images for the proper orientation and documentation of lesions, which is useful for follow-up studies.

Another innovative feature of the ABUS is the coronal view, which is unavailable with HHUS. The ABUS acquires an entire series of consecutive transverse images and reconstructs three-dimensional datasets of the entire breast volume, which can be reformatted into three views, including sagittal and coronal views. The ABUS allows the analysis of lesions in all three views, and the coronal view provides additional information for breast lesion detection and diagnosis (8,10,13-19). These studies mainly reported that the value of the coronal view was related to a comprehensive view of the breast anatomy, which provides information that can assist in breast cancer surgery and the visibility of the retraction phenomenon, which is an important characteristic of breast cancer. In the coronal view, the important information required for surgical planning is visualized with regard to the lesion location in relation to the nipple, as well as the segmental organization of the ductal system and surrounding tissue. The retraction phenomenon, which is visible in the coronal view, may help in the detection and differentiation between benign and malignant breast lesions.

However, supplemental ABUS screening also increases recall rates, leading to biopsy, with decreased positive predictive values (7, 20). In addition, ABUS requires interpretation of the whole breast, which is another challenge because this possibly increases the burden on the reader. Thus, we aimed to identify an accurate and efficient method of interpreting ABUS findings. We assessed the potential usefulness of the coronal view for improving the detection accuracy of breast lesions and reading times compared with that of the conventional transverse view.

Materials and Methods

Study Design and Ethics

In this retrospective, multicase, observer study, we used cancer-enriched datasets of ABUS images at a single institution. This study was conducted in accordance with the Declaration of Helsinki and approved by the institutional review board of Hokuto Hospital (approval number: 1034; date: October 23, 2018). The informed consent requirement was waived owing to the use of anonymized datasets.

Cases and Datasets

Our dataset comprised 114 ABUS cases with both coronal and transverse views obtained at our institution between October 2015 and September 2018. The cases were randomly and blindly selected by a radiological technologist. Two physicians who were not involved in this study reviewed the scan datasets to ensure suitability for analysis. The exclusion criteria were as follows: 1) a diagnosis of cancer by stereo-guided biopsy; 2) the presence of more than two malignant lesions; 3) the presence of more than five lesions; 4) the presence of a mass measuring ≥3 cm, and 5) a history of breast biopsy or surgery.

Image Acquisition

The Invenia™ ABUS (GE Healthcare, Chicago, IL, USA) was operated by one of five experienced radio technologists. Each breast was imaged with an automated 15.4 cm, 6–14 MHz, linear-array transducer. Three scans were performed for each breast (anteroposterior, lateral, and medial), although however, small breasts were imaged using two scans. Additional scans were performed as necessary for complete breast coverage.

Image Interpretation

The 114 scan datasets were assessed by 10 physicians from multiple institutions (5 Japanese and 5 Thai observers): 1 radiologist (with no experience using the ABUS), 1 internist (with 33 months of ABUS experience), and 8 breast surgeons (with ABUS experience ranging from 0–54 months). All observers completed the Invenia™ ABUS Mastery Program (Physician's Training) before study participation.

The scan datasets were anonymized and presented to the observers in the same order between June and October 2019. The observers interpreted the coronal and transverse views independently and while blinded to personal information or the results of the other view. Initially, the 114 ABUS scan datasets was interpreted in the coronal view and after a 4-week refresh period, they images were interpreted in the transverse view, thus ensuring that the observers had access to only the coronal or transverse view at any given time. A "coronal comparison" panel was displayed for coronal view reading (Figure 1) and a "transverse comparison" panel for transverse view reading (Figure 2).

The observers assessed each case for the presence or absence of abnormalities and were asked to complete a form to indicate the lesion locations and to report their confidence level on the presence of lesions. Confidence was assessed using a continuous rating scale from 0 to 1, with 0 corresponding to "definitely no lesion" and 1 to "definitely a lesion." This study focused on the detection of lesions rather than the discrimination between benign and malignant lesions. The assessments for lesions at different locations were excluded as false positives. The reading times for all observers for each of the coronal and transverse view interpretations were also recorded. The total reading time per day was limited to one hour to avoid the influence of fatigue.

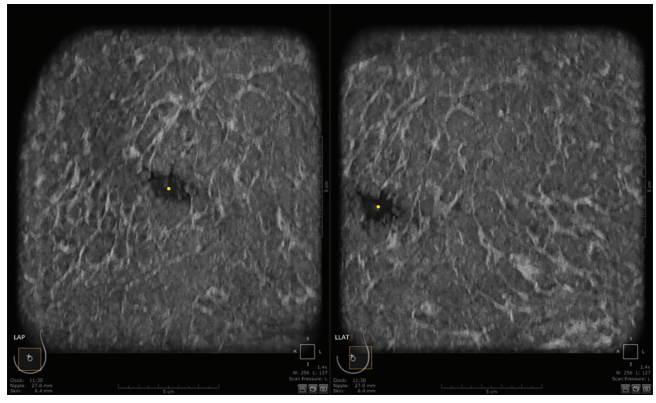

Figure 1. Coronal panel for coronal view reading. The left breast (anteroposterior, lateral) is shown. The yellow dots on the coronal view indicate the nipple positions

Statistical Analysis

Differences in the detection accuracy between the coronal and transverse views were statistically compared using the free-response receiver operating characteristic (FROC) analysis method for continuously distributed test results. The average reading time of each dataset was analyzed for each view and compared using a paired t-test. All statistical analyses were performed using JAFROC software version 4.2 (21). A $p<0.05$ was considered statistically significant.

Results

The selected scan datasets included 114 cases [healthy, n = 40 (5.1%); benign, n = 35 (30.7%); malignant, n = 39 (34.2%)] with 105 lesions (66 benign and 39 malignant lesions) from 83 women (mean age, 54±9 years) (Table 1).

In total, 2, 3, and 4 scans were performed in 83 (72.8%), 28 (24.6%), and 3 (2.6%) breasts, respectively.

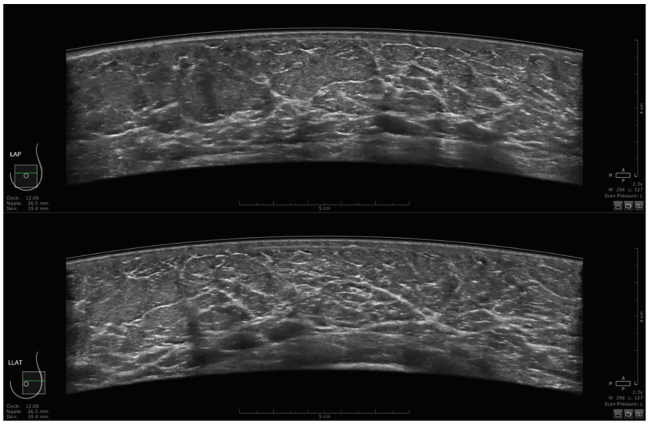

Figure 2. Transverse panel for transverse view reading. The left breast (anteroposterior, lateral) is shown

Table 1. Description of study sample (n = 114 breasts of 83 women)

Characteristic	Value
Age (years)	53.9 (40–69)
Age group	
40–49 years	42 (36.8)
50–59 years	36 (31.6)
60–69 years	36 (31.6)
Number of lesions per case	
0	40 (35.1)
1	53 (46.5)
2	14 (12.3)
3	5 (4.4)
4	1 (0.9)
5	1 (0.9)

Data are presented as the mean [range] or as numbers and percentages (%); percentages are rounded off

In addition, 82 mass lesions [78.1%; mean size, 10.6 mm; median (range), 9.0 mm (2.3–25.8 mm)] and 23 hypoechoic non-mass lesions [21.9%; mean size, 26.3 mm; median (range), 21.2 mm (5.5–65.3 mm)] were identified. Ultrasound-guided vacuum-assisted needle biopsy (VAB) (EnCor™, 10G, Becton, Dickinson and Company, Franklin Lakes, NJ, USA) was performed in 45 of the 114 cases, of which 6 and 39 cases had benign and malignant lesions, respectively. The pathological characteristics are shown in Table 2. The benign group included 6 VAB-confirmed cases and 29 non-VAB cases that showed no changes after >2 years of follow-up.

The figure of merit for the coronal view was slightly lower than that for the transverse view, although the difference was not statistically significant (0.740 vs. 0.745, respectively; p = 0.72) (Figure 3). Sensitivity, specificity, accuracy, and positive and negative predictive values for both coronal and transverse view are listed in Table 3. The average number of false negative benign and malignant lesions was 16.7 and 6.1 for the coronal view and 14.4 and 5.4 for the transverse view (Table 4), respectively. We defined a false negative as a rating of

Table 2. Pathological characteristics of breast lesions (n = 105 lesions in 74 breasts)

Pathological characteristic	Value
Benign	66 (62.9)
Intraductal papilloma	3 (2.9)
Fibrocystic change	2 (1.9)
Fibroadenoma	1 (1.0)
No change after >2 years follow-up	60 (57.1)
Malignant	39 (37.1)
Scirrhous carcinoma	12 (11.4)
Papillotubular carcinoma	9 (8.6)
Solid-tubular carcinoma	8 (7.6)
DCIS	6 (5.7)
Invasive lobular carcinoma	2 (1.9)
Mucinous carcinoma	1 (1.0)
Apocrine carcinoma	1 (1.0)

Data are presented as numbers and percentages (%); percentages are rounded off; DCIS: Ductal carcinoma *in situ*

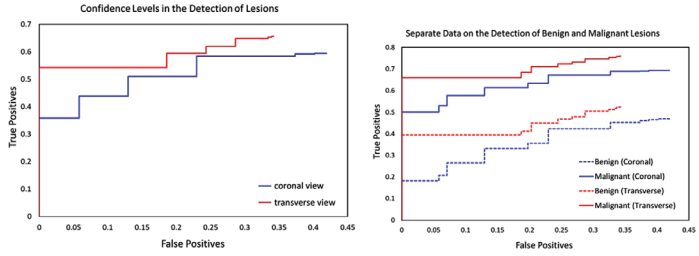

Figure 3. A) The free-response receiver operating characteristic curve revealed no significant difference in the average confidence levels in the detection of lesions between the coronal and transverse views (figure of merit=0.740 *vs.* 0.745, respectively; p = 0.718) across all observers. B) Separate data on the detection of both benign and malignant lesions showing the lower detection of benign by both coronal and transverse views

<50 on a continuous scale. The average reading time was significantly shorter for the coronal than transverse views (149.7 vs. 200.3 seconds per case, $p = 0.003$).

The characteristics of the malignant cases that most observers could not detect, and which at least six observers scored 0 on the scale, are summarized in Tables 5 and 6.

Five malignant cases were identified in which most observers could not detect the lesions in the coronal view although they were able to detect them in the transverse view. Two examples are shown in Figures 4 and 5. Moreover, two malignant cases were identified in which most observers could not detect the lesions in the transverse view although they could detect them in the coronal view (Figures 6 and 7). Table 5 summarizes the characteristics of hypoechoic non-mass lesions in four cases that were difficult to detect in the coronal view. The characteristics of a hypoechoic non-mass lesion differ from that of the surrounding parenchyma and do not conform to the definition of a "mass".

Discussion and Conclusion

We observed that the coronal view obtained using and ABUS was associated with a shorter reading time while maintaining detection

Table 3. Sensitivity, specificity, accuracy, and positive and negative predictive values for the coronal and transverse views

	#1	#2	#3	#4	#5	#6	#7	#8	#9	#10	Average
Coronal											
Sensitivity	58.1	5.27	66.2	79.7	67.6	83.8	70.3	74.3	74.3	64.9	69.2
Specificity	92.5	97.5	82.5	27.5	100	22.5	95.0	57.5	55.0	75.0	70.5
Accuracy	70.2	68.4	71.9	61.4	79.0	62.3	79.0	68.4	67.5	68.4	69.7
PPV	93.5	97.5	87.5	67.1	100	66.7	96.3	76.4	75.3	82.8	84.3
NPV	54.4	52.7	56.9	42.3	62.5	42.9	63.3	54.8	53.7	53.6	53.7
Transverse											
Sensitivity	79.7	39.2	66.2	73.0	71.6	91.9	70.3	79.7	82.4	78.4	73.2
Specificity	82.5	100	100	30.0	100	35.0	95.0	72.5	72.5	62.5	75.0
Accuracy	80.7	60.5	78.1	57.9	81.6	71.9	79.0	77.2	79.0	72.8	73.9
PPV	89.4	100	100	65.9	100	72.3	96.3	84.3	84.7	79.5	87.2
NPV	68.8	47.1	61.5	37.5	65.6	70.0	63.3	65.9	69.1	61.0	61.0

Data are presented as percentages (%). Percentages are rounded off; PPV: Positive predictive value; NPV: Negative predictive value

Table 4. Number of false negative benign and malignant lesions

	#1	#2	#3	#4	#5	#6	#7	#8	#9	#10	Average
Benign											
Coronal	24	24	19	11	17	8	19	14	12	19	16.7
Transverse	14	28	20	17	11	6	17	10	9	12	14.4
Malignant											
Coronal	7	11	6	4	7	4	3	5	7	7	6.1
Transverse	1	17	5	3	10	0	5	5	4	4	5.4

Data are presented as numbers, averages are rounded off

Table 5. Characteristics of the malignant cases that were difficult to detect in coronal view

	Pathology	Size (mm)	Findings
#1	Papillotubular carcinoma	14.0	Mass behind the nipple
#2	DCIS	17.6	Hypoechoic non-mass lesion behind the nipple
#3	DCIS	46.6	Hypoechoic non-mass lesion
#4	DCIS	65.3	Hypoechoic non-mass lesion
#5	Invasive lobular carcinoma	16.7	Hypoechoic non-mass lesion

DCIS: Ductal carcinoma *in situ*

Table 6. Characteristics of the malignant cases that were difficult to detect in transverse view

	Pathology	Size (mm)	Findings
#1	Papillotubular carcinoma	8.0	Mass with retraction
#2	Papillotubular carcinoma	10.1	Mass with retraction

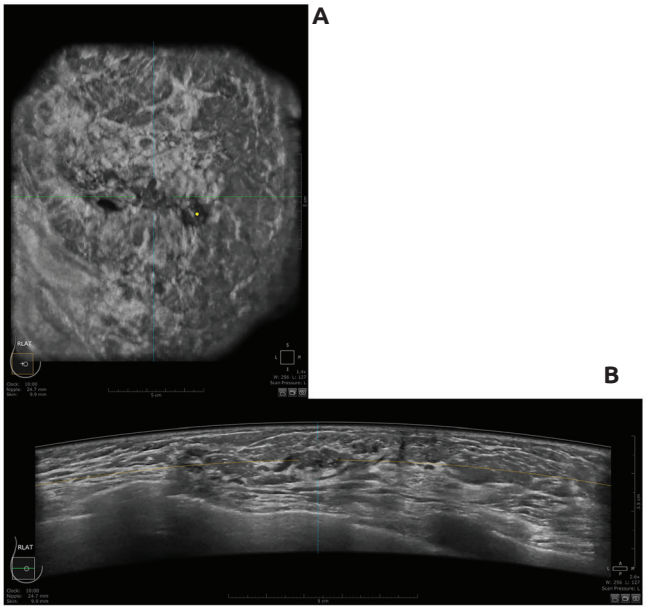

Figure 4. Images of a 50-year-old woman with ductal carcinoma *in situ* in the upper outer quadrant of the right breast. The lesion is visible at the center of the cross. A) The hypoechoic non-mass lesion could be difficult to detect in the coronal view, probably because it resembles subcutaneous fat entering the mammary gland. B) The transverse view in the lateral images shows the hypoechoic non-mass lesion

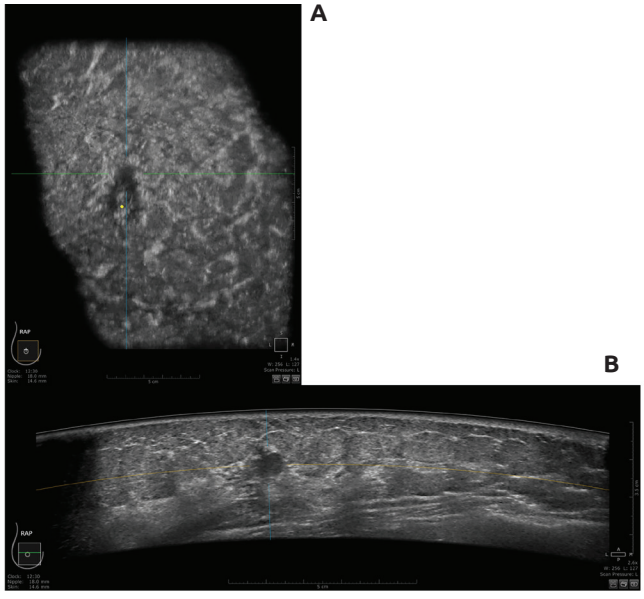

Figure 5. Images of a 55-year-old woman with a 14-mm papillotubular carcinoma located behind the nipple in the right breast. The lesion is visible at the center of the cross. A) The lesion behind the nipple is difficult to detect in the coronal view. B) The transverse view in the anteroposterior image shows the hypoechoic mass

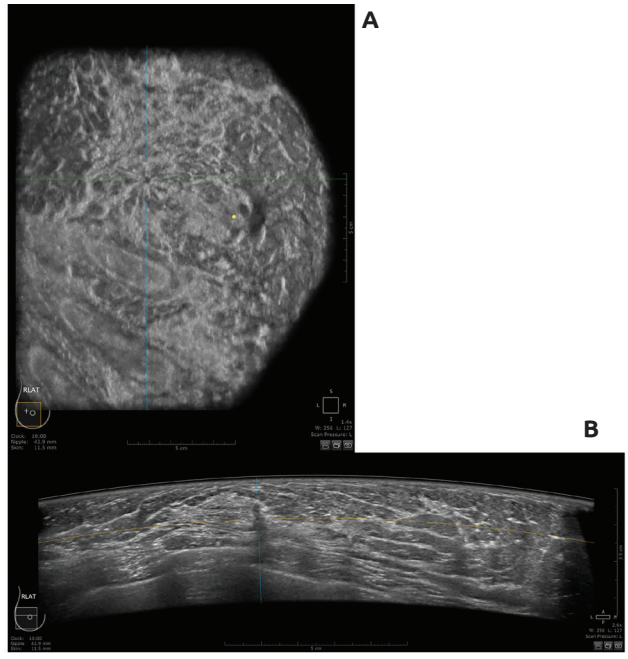

Figure 6. Images of a 50-year-old woman with an 8-mm papillotubular carcinoma in the upper outer quadrant of the right breast. The lesion is visible at the center of the cross. A) The coronal view in the lateral images shows a small mass with retraction. B) A small mass with shadowing could be difficult to detect because it appears as shadowing from dense fibroglandular tissue in the transverse view

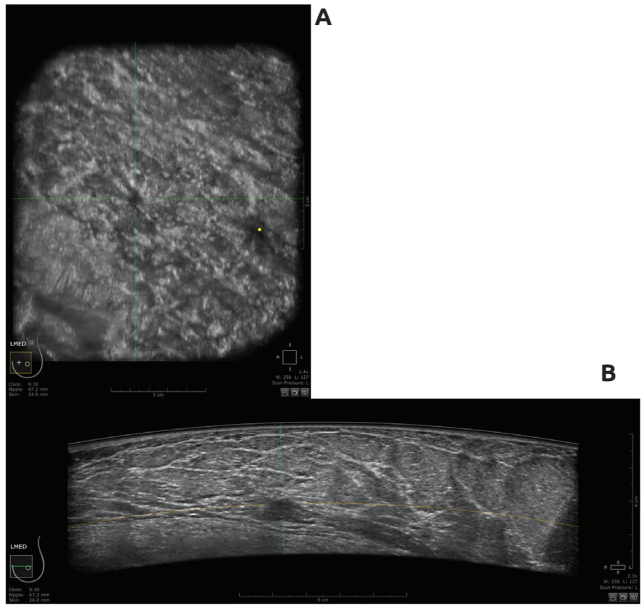

Figure 7. Images of a 58-year-old woman with a 10-mm papillotubular carcinoma in the upper inner quadrant of the left breast. The lesion is visible at the center of the cross. A) The lesion is easier to detect by identifying retraction in the coronal view. B) The lesion is indistinct in the transverse view because it is a deep mass

accuracy for breast lesions when compared with the conventional transverse view. Understanding the pitfalls in the interpretation of each view may improve the evaluation quality.

In this study, most observers could not detect hypoechoic non-mass lesions and lesions located behind the nipple in the coronal view. Hypoechoic non-mass lesions are difficult to detect in the coronal view because they resemble subcutaneous fat entering the mammary gland. Detecting lesions located behind the nipple in the coronal view was also difficult because of overlap between the lesion and the nipple. Meanwhile, even if the lesion is indistinct in the transverse view because it is a small or deep mass, it might be easier to detect by identifying retractions in the coronal view. Collectively, these findings support the interpretation of ABUS images; hypoechoic non-mass lesions and lesions located behind the nipple should be carefully investigated in the transverse view, and a small or deep mass that is difficult to detect in the transverse view could be detected by carefully identifying retraction in the coronal view.

Kim et al. (22) reported that the ABUS has a lower capability for detecting non-mass versus mass-type lesions, with a detection rate of 98% for mass-type and 77% for non-mass lesions. The current study revealed that hypoechoic non-mass lesions are difficult to detect in the coronal view, and the transverse view should be examined in order to detect these lesions are detected.

Our results showed that a lesion located behind the nipple is a cause of false negatives because the lesion overlaps with the nipple. Although lesions located behind the nipple should be carefully sought for in the transverse view, shadowing artifacts behind the nipple may also cause misinterpretation in the transverse view. Several studies have reported the misinterpretation of ABUS findings owing to artifacts (23, 24). Our study included a false negative case in which a micromass with shadowing appeared to be shadowing from dense fibroglandular tissue in the transverse view. However, this could be interpreted as a mass with retraction in the coronal view.

The retraction phenomenon has high sensitivity (70–89%) and specificity (96–100%) for cancer detection (15, 17, 18) and is a diagnostic imaging sign of cancer (13). Our study also showed that retraction was easy to detect in the coronal view. Zheng et al. (18) reported that retraction in the coronal view is the strongest independent predictor of malignant masses and has a high diagnostic value in the differentiation between benign and malignant breast masses.

Figure 3B shows that the detection of benign lesions was lower than that of malignant lesions while Table 4 shows that the false negative malignant lesions were fewer than the benign lesions using both the coronal and transverse views, consistent with the findings of Güldogan et al. (11) showing that ABUS detected fewer benign lesions than HHUS while having a similar performance to HHUS for cancer detection. This indicates that ABUS has the potential to decrease the incidence of false positives while maintaining the detection of malignant lesions.

The interpretation time when using ABUS, which is associated with an increased burden on readers, has been reported in some studies (24, 25). Chae et al. (25) analyzed the average interpretation times for the coronal and transverse views and found a markedly longer mean interpretation time for the transverse view (3.83±1.71 minutes vs. 5.57±2.21 minutes). Similar results were obtained in the current study. The detection time was faster in the coronal view conceivably because of the small number of slices from the superficial skin level to the thoracic wall. We examined the differences in interpretation time based on observer experience levels. The interpretation time for the readers with 0 months of experience and others was 101.2 and 161.8 seconds for the coronal view and 197.2 and 201.0 seconds for the transverse view, respectively. With the coronal view, the result indicated that the reading time was shorter for those with 0 months of experience, possibly because the sensitivity of the coronal view was lower for those readers. The sensitivity, specificity, accuracy, and positive and negative predictive values for readers with 0 months of experience and others were 55.4%, 95.0%, 69.3%, 95.5%, 53.6% and 72.6%, 64.4%, 69.7%, 81.5%, 53.7%, respectively.

The detection accuracy in our study might have been low for two reasons. First, two observers had no experience with the ABUS prior to the study, and the pre-study training might have been insufficient. Second, 28 out of 105 lesions were <5 mm, which were more difficult to detect.

Study Limitations

This study has some limitations, including the retrospective design and small sample size of cancer-enriched datasets, which were selected at our discretion and may have caused selection bias. Moreover, the proportions of case types were not representative of the general population. However, although the selection bias affected the FROC results, it did not impact the comparisons between the coronal and transverse views. The ABUS images were interpreted using either coronal or transverse views alone, which differs from an actual screening setting. Greater familiarity with the transverse versus coronal view might lead to bias. Therefore, the results of this study cannot be applied to general breast cancer screening and must be interpreted with caution. In Japan, breast surgeons often interpret ultrasound images for screening and so the percentage of breast surgeons among the observers who participated in this study was high. Finally, we did not compare the results between specialties or countries.

In conclusion, the coronal view obtained when using ABUS was useful for interpretation and associated with significantly shorter reading times than those of the conventional transverse view, while maintaining breast lesion detection accuracy. In addition, considering the characteristics of each view, interpretation accuracy may be increased by interpreting the mass with retraction in the coronal view and focusing on hypoechoic non-mass lesions and lesions located behind the nipples in the transverse view. An accurate use of each view will improve the diagnostic performance of the ABUS in breast cancer screening. In this study, only the detection of lesions was verified. In the future, we plan to verify the discrimination between benign and malignant lesions. Furthermore, we hope that computer-aided detection and artificial intelligence will provide support for interpretation, leading to greater uptake and widespread of the ABUS.

Ethics Committee Approval: This study was conducted in accordance with the Declaration of Helsinki and approved by the institutional review board of Hokuto Hospital (approval number: 1034; date: October 23, 2018).

Informed Consent: The informed consent requirement was waived owing to the use of anonymized datasets.

Peer-review: Externally and internally peer-reviewed.

Authorship Contributions

Concept: M.S., R.N., K.N., H.K., M.N., S.N.; Design: M.S., R.N., K.N., H.K.; Data Collection or Processing: M.S., M.N.; Analysis or Interpretation: M.S., R.N.; Literature Search: M.S.; Writing: M.S., S.N.

Conflict of Interest: No conflict of interest was declared by the authors.

Financial Disclosure: This research was supported by a grant from GE Healthcare.

References

1. Tabár L, Fagerberg CJ, Gad A, Baldetorp L, Holmberg LH, Gröntoft O, et al. Reduction in mortality from breast cancer after mass screening with mammography. Randomised trial from the Breast Cancer Screening Working Group of the Swedish National Board of Health and Welfare. Lancet 1985; 1: 829-832. (PMID: 2858707) [Crossref]
2. Mandelson MT, Oestreicher N, Porter PL, White D, Finder CA, Taplin SH, et al. Breast density as a predictor of mammographic detection: comparison of interval- and screen-detected cancers. J Natl Cancer Inst 2000; 92: 1081-1087. (PMID: 10880551) [Crossref]
3. Berg WA, Blume JD, Cormack JB, Mendelson EB, Lehrer D, Böhm-Vélez M, et al. Combined screening with ultrasound and mammography vs. mammography alone in women at elevated risk of breast cancer. JAMA 2008; 299: 2151-2163. (PMID: 18477782) [Crossref]
4. Stomper PC, D'Souza DJ, DiNitto PA, Arredondo MA. Analysis of parenchymal density on mammograms in 1353 women 25–79 years old. AJR 1996; 167: 1261-1265. (PMID: 8911192) [Crossref]
5. Rella R, Belli P, Giuliani M, Bufi E, Carlino G, Rinaldi P, et al. Automated breast ultrasonography (ABUS) in the screening and diagnostic setting: indications and practical use. Acad Radiol 2018; 25: 1457-1470. (PMID: 29555568) [Crossref]
6. Giuliano V, Giuliano C. Improved breast cancer detection in asymptomatic women using 3D-automated breast ultrasound in mammographically dense breasts. Clin Imaging 2013; 37: 480-486. (PMID: 23116728) [Crossref]
7. Brem RF, Tabár L, Duffy SW, Inciardi MF, Guingrich JA, Hashimoto BE, et al. Assessing improvement in detection of breast cancer with three-dimensional automated breast US in women with dense breast tissue: the SomoInsight study. Radiology 2015; 274: 663-673. (PMID: 25329763) [Crossref]
8. Wang HY, Jiang YX, Zhu QL, Zhang J, Dai Q, Liu H, et al. Differentiation of benign and malignant breast lesions: a comparison between automatically generated breast volume scans and handheld ultrasound examinations. Eur J Radiol 2012; 81: 3190-3200. (PMID: 22386134) [Crossref]
9. Kuzmiak CM, Ko EY, Tuttle LA, Steed D, Zeng D, Yoon SC. Whole breast ultrasound: comparison of the visibility of suspicious lesions with automated breast volumetric scanning versus hand-held breast ultrasound. Acad Radiol 2015; 22: 870-879. (PMID: 25872862) [Crossref]
10. Wang ZL, Xu JH, Li JL, Huang Y, Tang J. Comparison of automated breast volume scanning to hand-held ultrasound and mammography. Radiol Med 2012; 117: 1287-1293. (PMID: 22744341) [Crossref]
11. Güldogan N, Yılmaz E, Arslan A, Küçükkaya F, Atila N, Arıbal E. Comparison of 3D-automated breast ultrasound with handheld breast ultrasound regarding detection and BI-RADS characterization of lesions in dense breasts: a study of 592 cases. Acad Radiol 2022; 29: 1143-1148. (PMID: 34955365) [Crossref]
12. Chou YH, Tiu CM, Chen J, Chang RF. Automated full-field breast ultrasonography: the past and the present. J Med Ultrasound 2007; 15: 31-44. [Crossref]
13. van Zelst JCM, Mann RM. Automated three-dimensional breast US for screening: technique, artifacts, and lesion characterization. Radiographics 2018; 38: 663-683. (PMID: 29624482) [Crossref]
14. Vourtsis A, Kachulis A. The performance of 3D ABUS versus HHUS in the visualisation and BI-RADS characterisation of breast lesions in a large cohort of 1,886 women. Eur Radiol 2018; 28: 592-601. (PMID: 28828640) [Crossref]
15. Lin X, Wang J, Han F, Fu J, Li A. Analysis of eighty-one cases with breast lesions using automated breast volume scanner and comparison with handheld ultrasound. Eur J Radiol 2012; 81: 873-878. (PMID: 21420814) [Crossref]
16. Wojcinski S, Farrokh A, Hille U, Wiskirchen J, Gyapong S, Soliman AA, et al. The automated breast volume scanner (ABVS): initial experiences in lesion detection compared with conventional handheld B-mode ultrasound: a pilot study of 50 cases. Int J Womens Health 2011; 3: 337-346. (PMID: 22114526) [Crossref]
17. Kalmantis K, Dimitrakakis C, Koumpis Ch, Tsigginou A, Papantoniou N, Mesogitis S, et al. The contribution of three- dimensional power doppler imaging in the preoperative assessment of breast tumors: a preliminary report. Obstet Gynecol Int 2009; 2009: 530579. (PMID: 20011062) [Crossref]
18. Zheng FY, Yan LX, Huang BJ, Xia HS, Wang X, Lu Q, et al. Comparison of retraction phenomenon and BI-RADS-US descriptors in differentiating benign and malignant breast masses using an automated breast volume scanner. Eur J Radiol 2015; 84: 2123-2129. (PMID: 26272029) [Crossref]
19. Van Zelst JC, Platel B, Karssemeijer N, Mann RM. Multiplanar reconstructions of 3D automated breast ultrasound improve lesion differentiation by radiologists. Acad Radiol 2015; 22: 1489-1496. (PMID: 26345538) [Crossref]
20. Kelly KM, Dean J, Comulada WS, Lee SJ. Breast cancer detection using automated whole breast ultrasound and mammography in radiographically dense breasts. Eur Radiol 2010; 20: 734-742. (PMID: 19727744) [Crossref]
21. Chakraborty DP, Berbaum KS. Observer studies involving detection and localization: modeling, analysis, and validation. Med Phys 2004; 31: 2313-2330. (PMID: 15377098) [Crossref]
22. Kim Y, Kang BJ, Kim SH, Lee EJ. Prospective study comparing two second-look ultrasound techniques: handheld ultrasound and an automated breast volume scanner. J Ultrasound Med 2016; 35: 2103-2112. (PMID: 27503758) [Crossref]
23. Grubstein A, Rapson Y, Gadiel I, Cohen M. Analysis of false-negative readings of automated breast ultrasound studies. J Clin Ultrasound 2017; 45: 245-251. (PMID: 28295423) [Crossref]
24. Skaane P, Gullien R, Eben EB, Sandhaug M, Schulz-Wendtland R, Stoeblen F. Interpretation of automated breast ultrasound (ABUS) with and without knowledge of mammography: a reader performance study. Acta Radiol 2015; 56: 404-412. (PMID: 24682405) [Crossref]
25. Chae EY, Cha JH, Kim HH, Shin HJ. Comparison of lesion detection in the transverse and coronal views on automated breast sonography. J Ultrasound Med 2015; 34: 125-135. (PMID: 25542948) [Crossref]