

# Pseudoangiomatous Stromal Hyperplasia of the Breast: Mammosonography and Elastography Findings with a Histopathological Correlation

## Psödoanjimatöz Stromal Hiperplazi Bildirilen Kitlenin Mamo-Sonografi ve Elastografi Bulguları

Ebru Yılmaz<sup>1</sup>, Fatma Zeynep Güngören<sup>1</sup>, Ayhan Yılmaz<sup>1</sup>, Tuğrul Örmeci<sup>1</sup>, Gonca Özgün<sup>3</sup>, Sibel Çağlar Atacan<sup>2</sup>, İsmail Sinan Duman<sup>4</sup>

<sup>1</sup>Department of Radiology, Medipol University Faculty of Medicine, İstanbul, Turkey

<sup>2</sup>Department of Radiology, Forensic Medicine Institute, İstanbul, Turkey

<sup>3</sup>Department of Pathology, Medipol University Faculty of Medicine, İstanbul, Turkey

<sup>4</sup>Clinic of Radiology, Gaziosmanpaşa Taksim Training and Research Hospital, İstanbul, Turkey

### ABSTRACT

Pseudoangiomatous stromal hyperplasia (PASH) is a rare benign mesenchymal proliferative lesion of the breast. In this study, we aimed to show a case of PASH with mammographic and sonographic features, which fulfill the criteria for benign lesions and to define its recently discovered elastography findings. A 49-year-old premenopausal female presented with breast pain in our outpatient surgery clinic. In ultrasound images, a hypoechoic solid mass located at the 3 o'clock position in the periareolar region of the right breast was observed. Due to it was not detected on earlier mammographies, the patient underwent a tru-cut biopsy, although the mass fulfilled the criteria for benign lesions on mammography, ultrasound, and elastography. Elastography is a new technique differentiating between benign and malignant lesions. It is also useful to determine whether a biopsy is necessary or follow-up is sufficient.

**Keywords:** Pseudoangiomatous stromal hyperplasia, benign, breast, elastography

### ÖZ

Psödoanjimatöz stromal hiperplazi (PASH), memenin benign mezenkimal proliferatif hastalıklarındandır. Stromal miyofibroblastların proliferasyonu sonucu oluşur. Tipik olarak pre ve perimenapozal kadınlarda görülür. Memede ağrı şikayetiyle genel cerrahi polikliniğine başvuran kırk dokuz yaşındaki premenapozal kadın hastanın yapılan meme ultrasonografisinde (US) sağ meme saat 3 hizasında periareolar alanda düzgün sınırlı, cilde paralel uzanımlı, homojen hipoeoik solid kitle saptandı. Kitlenin mamografik ve sonografik özellikleri benign kriterler taşımasına rağmen önceki mamogramlarda izlenmemesi nedeniyle kalın iğne biyopsisi yapıldı. Patoloji sonucu PASH olarak bildirilen hastanın mevcut mamografi, sonografi bulgularını tekrar gözden geçirmeyi ve elastografi bulgularını sunmayı amaçladık.

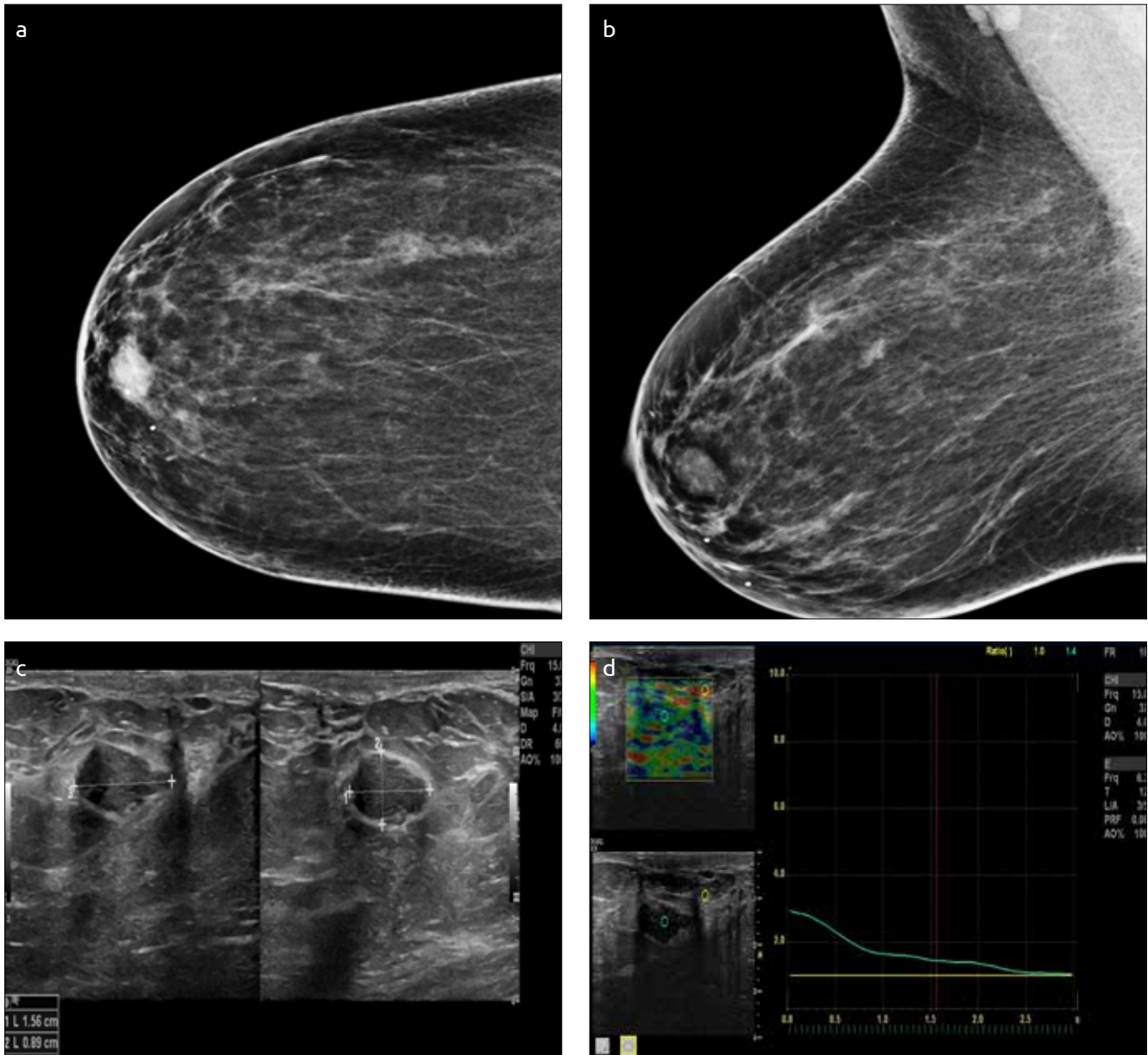
**Anahtar sözcükler:** PASH, Benign meme kitleleri, elastografi

### Introduction

Pseudoangiomatous stromal hyperplasia (PASH) is a benign mesenchymal proliferative lesion of the breast. It typically affects peri- and premenopausal women and occurs as a result of stromal myofibroblast proliferation. We aimed to present a case of pathologically proven PASH with its mammography, sonography, and elastography findings.

### Case Presentation

A 49-year-old premenopausal female presented with bilateral breast pain in our outpatient surgery clinic. With normal physical examination findings, she was referred to our radiology department where she underwent routine mammography. The mammography findings revealed an oval-shaped 15 × 12 mm-sized radiopacity that had the same density with the adjacent parenchyma, which was observed in the retroareolar area of the right breast. The border of the lesion was covered by the adjacent parenchyma and therefore could not be clearly evaluated. In addition, structural distortion or microcalcification was not observed. The mammogram revealed a 15 × 12 mm-sized low density radiopaque lesion in the retroareolar region of the right breast. The border of the lesion was not clearly detected because it was covered by the adjacent parenchyma, which had the same density as the lesion. In comparison with the earlier mammographies, we found out that this lesion occurred within past 2 years. In ultrasonography (US) images, the lesion was verified as an oval-shaped, 16 × 9 × 19 mm-sized, well-circumscribed hypoechoic solid mass located in the periareolar area of the right breast at the 3 o'clock position. There was neither posterior acoustic enhancement nor shadowing. Its long axis was parallel to the skin surface and showed no prominent vascularization on Doppler US. On elastography, based on manual compression, the mass was coded in green-red. After analyzing the data, the elasticity score of the mass was 1.8, of the adjacent fat tissue was 1.3, and of the lesion/fat ratio was 1.4 (Figure 1). The reason why we offered a biopsy and a subsequent histopathological verification of the mass, although it fulfilled the criteria for benign lesions on



**Resim 1. a-d.** Case of pathologically proven PASH after the mass excision. Mammographies of right CC projection (a) and MLO projection, (b) an opacity in the retroareolar region of the right breast, (c) B Mode US, a well-circumscribed homogeneous hypoechoic mass with its long axis parallel to the skin surface, (d) Elastography; the mass coded in red-green and with a lesion/fat ratio of 1.4

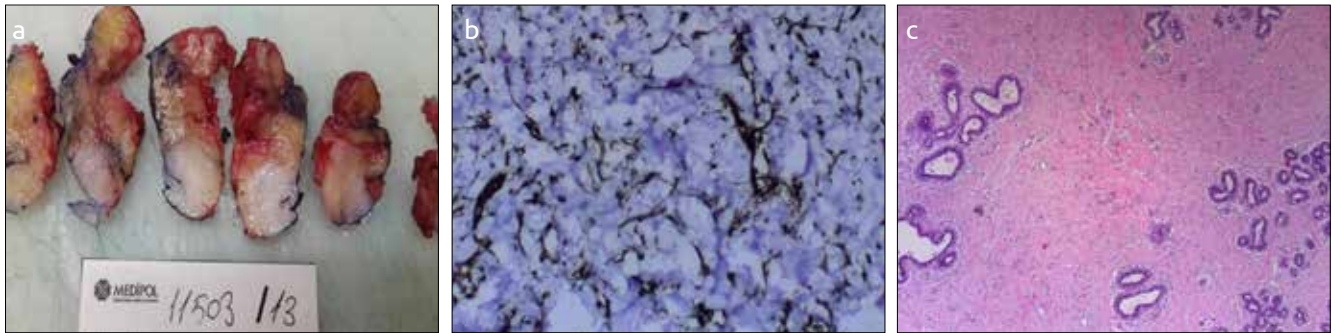
mammography, ultrasound, and elastography findings, was that it was not detected on earlier mammographies. The lesion was classified as BIRADS 4a (1), and the patient underwent US-guided 14-gauge core needle tru-cut biopsy (Bard Biopsy Systems TEMPE, AZ). The lesion that was pathologically proven PASH was excised because of patient choice (Figure 2).

### Discussion and Conclusions

PASH, according to the World Health Organization (WHO) classification, is one of the benign masses classified among mesenchymal tumors. It was first described in 1986 by Vuitch, Rosen, and Erlandson with nine cases as a mass that simulated vascular lesions containing stromal proliferation. It typically affects peri- and premenopausal females. It was also reported that PASH had occurred, albeit rarely, in males with gynecomastia, males on exogen hormones, and elderly females (2, 3). These findings provide additional evidence that PASH

is related with hormone levels and develops as a result of progesterone effects in breast tissue, which is under the influence of estrogen. Most of the reported cases in the literature demonstrate the presence of progesterone receptor activity and weak to no estrogen receptor activity (4). Our case was in the premenopausal period and had no history of exogenous estrogen usage.

Fibroadenoma, phyllodes tumor, hamartomas, lymphangioma, and particularly angiosarcomas are described among the differential diagnosis of PASH. Macroscopically, it is observed as a nodular pale pink or yellowish lesion with a size up to 17 cm. In PASH lesions, there are no erythrocytes in slit-like spaces, and this finding is useful for differentiating PASH from angiosarcomas (5). Furthermore, it is remarkable that angiosarcomas do not contain epithelial cells. Angiosarcomas can be confused histologically with PASH. It is important to differentiate the two lesions because of differences in prognosis and treatment. PASH is benign, necessitating no further intervention, whereas highly



**Resim 2. a-c.** Case of pathologically proven PASH after the mass excision, (a) Macroscopic findings, (b) Stromal myofibroblasts showing diffuse expression with an immunohistochemical stain for CD34, (c) HE staining of anastomosing spaces in the dense collagenous stromal component between normal ductal structures

vascular angiosarcoma is a tumor that is susceptible to bleeding and it is generally managed with wide local excision and chemotherapy (6). The differentiation of the two entities is based on histology, with immunohistochemical staining for CD31 and Factor VIII. Angiosarcoma is positive for CD21 and Factor VIII, whereas PASH is negative for both. PASH is differentiated from lymphangiosarcomas by being D2-40 negative.

The clinical spectrum varies from focal palpable to nonpalpable mass-like nodules (nodular PASH) to diffuse breast involvement (7). Nodular PASH is uncommon and is found in only 0.4% of breast biopsies. Non-mass-forming PASH is generally an incidental finding and has been reported in 23% of breast biopsies (8). As in our case, nodular PASH generally manifests as a painless, mobile, circumscribed, palpable mass (2, 7).

Based on radiological analysis, there are no specific or diagnostic features. Mammographically, these lesions are generally well defined with a smooth border and do not contain calcifications. However, their margins may be ill defined or it may be covered by the adjacent parenchyma. In US images, the lesions are generally observed as well-defined solid masses with hypoechogenicity or heterogeneous echogenicity and with sound attenuation characteristics varying from posterior enhancement to mild posterior shadowing (9, 10). In US images, some large lesions contain numerous lace-like reticular areas with scattered cystic changes (11). The most common mammographic feature is a well-circumscribed generally homogeneous mass-like lesion or asymmetric density. Spiculated lesions, distortion, and calcification exclude the diagnosis of PASH. Mammographic and sonographic features are nonspecific and display characteristics of benign lesions. Consistent with the literature, the mass of our case had benign mammographic and sonographic features. However, because of its recent existence and the age of the patient, we classified the mass as BI-RADS 4a and biopsy was performed.

Recently, elastography has become available, and it enables us to differentiate between benign and malignant breast lesions. The main principle of elastography is that after compression, stiff tissues displace less than softer tissues. The displacement of the tissue due to compression helps us to determine the tissue stiffness; therefore, it is useful to detect breast cancer. Soft tissues are coded in the red range and stiff tissues in the blue range. The elasticity scores are measured by placing the region of interest (ROI) within the tissue and in the adjacent fat tissue. The mean elasticity score of malignant masses and benign lesions was 4.2 and 2.1, respectively. In our study, the elasticity score of the mass was 1.8 and the lesion/fat ratio was 1.4. These scores are related to benign lesions (12-14).

In conclusion, based on radiological analyses, the most important point is differentiating benign lesions from malignant lesions and classifying them correctly in BIRADS lexicon. The mass that had benign mammographic and sonographic features showed benign characteristics also on elastography. Such cases should be supported by a wide series. Thus, we assume that the number of unnecessary involvements will decrease.

**Informed Consent:** Written informed consent was obtained from patient who participated in this study.

**Peer-review:** Externally peer-reviewed.

**Author Contributions:** Concept - E.Y., F.G.; Design - E.Y., F.G.; Supervision - T.Ö., A.Y.; Funding - S.A., F.G., İ.D.; Materials - F.G., E.Y., G.Ö.; Data Collection and/or Processing - E.Y., F.G., A.Y.; Analysis and/or Interpretation - E.Y., F.G., T.Ö.; Literature Review - F.G., E.Y., A.Y.; Writer - E.Y., F.G., G.Ö., A.Y.; Critical Review - T.Ö., A.Y., S.A.; Other - G.Ö., İ.D., S.A.

**Conflict of Interest:** No conflict of interest was declared by the authors.

**Financial Disclosure:** The authors declared that this study has received no financial support.

**Hasta Onamı:** Yazılı hasta onamı bu çalışmaya katılan hastadan alınmıştır.

**Hakem değerlendirmesi:** Dış bağımsız.

**Yazar Katkıları:** Fikir - E.Y., F.G.; Tasarım - E.Y., F.G.; Denetleme - T.Ö., A.Y.; Kaynaklar - S.A., F.G., İ.D.; Malzemeler - F.G., E.Y., G.Ö.; Veri toplanması ve/veya işleme - E.Y., F.G., A.Y.; Analiz ve/veya yorum - E.Y., F.G., T.Ö.; Literatür taraması - F.G., E.Y., A.Y.; Yazıyı yazan - E.Y., F.G., G.Ö., A.Y.; Eleştirel İnceleme - T.Ö., A.Y., S.A.; Diğer - G.Ö., İ.D., S.A.

**Çıkar Çatışması:** Yazarlar çıkar çatışması bildirmemişlerdir.

**Finansal Destek:** Yazarlar bu çalışma için finansal destek almadıklarını beyan etmişlerdir.

## References

1. D'Orsi CJ, Sickles EA, Mendelson EB. ACR BI-RADS Atlas, Breast Imaging Reporting and Data System, Reston VA, American College of Radiology; 2013.
2. Irshad A, Ackerman SJ, Pope TLM, Moses CK, Rumbolt T, Panzegrav B. Rare breast lesions: Correlation of imaging and histologic features with WHO classification: RadioGraphics 2008; 28:1399-1414. (PMID:18794315) [CrossRef]
3. Bowman E, Oprea Gabriela, Okoli J, Gundry K, Rizzo M, Gabram-Mendola S, Manne U, Smith G, Pambuccian S, Bumpers HL. Pseudo-angiomatous Stromal Hyperplasia (PASH) of the Breast: A Series of 24 Patients. Breast J 2012; 18:242-247. (PMID: 22583194) [CrossRef]

4. Zanella M, Falconieri G, Lamovec J, Bittesini L. Pseudoangiomatous hyperplasia of the mammary stroma: true entity or phenotype? *Pathol Res Pract* 1998; 194:535-540. (PMID: 9779487) [\[CrossRef\]](#)
5. Sasaki Y, Kamata S, Saito K, Nishikawa Y, Ogawa J. Pseudoangiomatous stromal hyperplasia (PASH) of the mammary gland: report of a case. *Surgery Today* 2008; 38:340-343. (PMID: 18368324) [\[CrossRef\]](#)
6. Johnson CM, Garquilo GA. Angiosarcoma of the breast: a case report and literature review. *Curr Surg* 2002; 59:490-494. (PMID: 15727796) [\[CrossRef\]](#)
7. Castro CY, Whitman GJ, Sahin AA. Pseudoangiomatous stromal hyperplasia of the breast. *Am J Clin Oncol* 2002; 25:213-216. (PMID: 11943906) [\[CrossRef\]](#)
8. Polger MR, Denison CM, Lester S, Meyer JE. Pseudoangiomatous stromal hyperplasia: mammographic and sonographic appearances. *AJR Am J Roentgenol* 1996; 166:349-352. (PMID:8553945) [\[CrossRef\]](#)
9. Mercado CL, Naidrich SA, Hamele-Bena D, Fineberg SA, Buchbinder SS. Pseudoangiomatous stromal hyperplasia of the breast: sonographic features with histopathologic correlation. *Breast J* 2004; 10:427-432. (PMID: 15327497) [\[CrossRef\]](#)
10. Cohen MA, Morris EA, Rosen PP, Dershaw DD, Liberman L, Abramson AF. Pseudoangiomatous stromal hyperplasia: mammographic, sonographic and clinical patterns. *Radiology* 1996; 198:117-120. (PMID: 8539361) [\[CrossRef\]](#)
11. Teh HS, Chiang SH, Leung JW, Tan SM, Mancer JF. Rapidly enlarging tumoral pseudoangiomatous stromal hyperplasia in a 15-year-old patient: distinguishing sonographic and magnetic resonance imaging findings and correlation with histologic findings. *J Ultrasound Med* 2007; 26:1101-1106. (PMID: 17646374)
12. Yağtu M, Turan E, Turan CO. The Role of Ultrasographic Elastography in the Differential Diagnosis of Breast Masses and Its Contribution to Classical Ultrasonographic Evaluation *J Breast Health* 2014; 10:141-146.
13. Itoh A, Ueno E, Tohno E, Kamma H, Takahashi H, Shiina T, Yamakawa M, Matsumura T. Breast Disease: Clinical Application of US Elastography for Diagnosis. *Radiology* 2006; 239:341-350. (PMID: 16484352) [\[CrossRef\]](#)
14. Matsumura T, Tamano S, Mitake T. Development of freehand ultrasound elasticity imaging system and in vivo results. In: *Proceeding of the 1st International Conference on the Ultrasonic Measurement and Imaging of Tissue Elasticity*. Rochester, NY: University of Rochester 2002; 1:80.