

THE MUSCULUS STERNALIS: ULTRASONOGRAPHIC VERIFICATION OF A RARE BUT BENIGN MAMMOGRAPHIC FINDING

MUSCULUS STERNALIS: ENDER ANCAK BENIGN MAMOGRAFİK BULGUNUN ULTRASONOGRAFİK OLARAK DOĐRULANMASI

Ersen Alp Özbalcı, Feray Özgür Saraçođlu

Clinic of Radiology, LaMED Imaging Center, Izmir, Turkey

ABSTRACT

Screening mammography requires high-quality images and experienced radiologists. An improved technique with a systematic approach to patient positioning enables visualization of the deep parts of the breast. The sternalis muscle is occasionally observed in mammograms as a variant of the deep normal structures and may mimic a mass. The sternalis muscle is an uncommon anatomic variant of the chest wall musculature. It is located subcutaneously over the pectoralis muscle and has a parallel course to the sternum. It runs from the infraclavicular area to the caudal aspect of the breast. This inconsistent muscle has varying shapes, contours and sizes and may mimic a mass lesion on the craniocaudal (CC) mammogram. Familiarity with its mammographic appearance and ultrasonographic correlation is essential to avoid confusion with a malignant lesion. In this case report, we describe mammographic and ultrasonographic imaging findings of the sternalis muscle and review the literature.

Key words: Breast, the sternalis muscle, mammography

ÖZET

Tarama mamografisi yüksek kalitede mamogramlara ve deneyimli radyologlara ihtiyaç duyar. Sistematik yaklaşımla geliştirilmiş pozisyon verme teknikleri sayesinde memenin derin dokularının görüntülenmesi mümkün olmaktadır. Musculus sternalis mamogramlarda derin dokuların normal varyantı olarak karşımıza çıkmakta olup kitleyi taklit edebilmektedir. Sternal kas, göğüs duvarı kas yapılarının sık olmayan bir varyantıdır. Pektoral kas üzerinde subkutan dokuda yer alır ve sternuma paralel olarak seyreder. İnfraklavikular alandan meme kaudaline doğru uzanır. Bu varyatif kas yapısı çeşitli şekil, kontur ve boyutlarda olup kraniokaudal (CC) mamogramlarda kitleyi taklit edebilir. Malign lezyonlar ile karıştırmamak için mamografik ve ultrasonografik görünümlerine tanıdık olmak gerekmektedir. Bu olgu sunumunda sternal kasın mamografik ve ultrasonografik görüntüleme bulgularını tanımlayarak literatürü gözden geçirdik

Anahtar sözcükler: Meme, musculus sternalis, mamografi

Detecting breast cancer at a small size and an early stage can reduce mortality (1). Screening mammography and early detection have been shown to increase survival and to reduce mortality (2, 3). Standard screening mammography consists of craniocaudal (CC) and mediolateral oblique (MLO) projections. The overriding goal for positioning the CC view should be to include all of the posteromedial tissue. The proper CC view must include pectoral muscle at the posterior and the nipple should be in the midline.

The sternalis muscle is a supernumerary muscle located in the anterior thoracic region, running parallel to the sternum. Different anatomical studies have reported the prevalence of the sternalis

muscle to be 1.923.5% (4). It was first shown on mammography by Bradley et al. (5), who described it in six women.

Case Report

A forty-eight year old patient was interpreted in our centre for screening mammography. Standard CC and MLO views were obtained and interpreted with previous mammograms. CC mammogram demonstrated a developing density in the medial posterior part of the breast. The density was round in shape and the edges were well defined (Figure 1). As we interpreted that lesion as a developing density, ultrasound examination was performed. Ultrasonographic views showed approximately 5x35x70 mm muscle tissue over the right pectoralis muscle. The muscle tissue was well

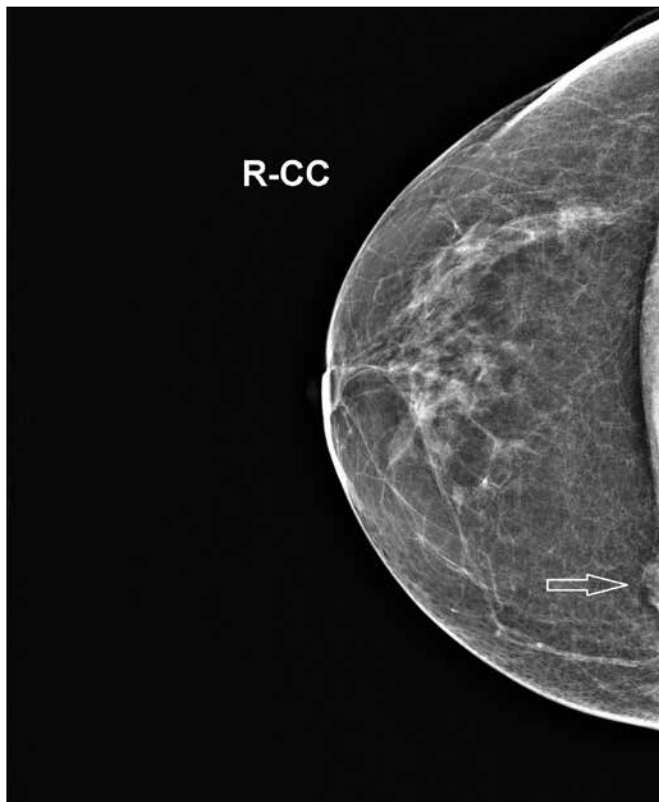


Figure 1. Forty-eight year old patient, screening mammogram, CC view. There is a round well-defined density at the posterior medial part of the breast.

formed, with a distinct fascia (Figure 2-4). After ultrasonographic verification of the sternal muscle, we reported the case as BI-RADS II and advised routine annual screening mammography.

Discussion and Conclusions

Breast cancer is the most common cancers and most common causes of death from cancer among women. Detecting breast cancer while it is still in situ or, if invasive, when it is 1 cm or less in diameter can reduce mortality. Screening mammography and early detection have been shown to increase survival (3, 4). Early detection of breast cancer depends on high-quality mammography, an appropriately short time between screenings, accurate interpretation and early intervention. Improvements have been made in mammographic equipment that have resulted in dedicated mammography units that firmly hold the breast in the field of view and provide high spatial resolution. The technologist is encouraged to tailor the examination to the patient's body habitus and physical condition. Adequate positioning requires pulling the breast away from the chest wall and compressing it onto the image receptor. Improved positioning for the craniocaudal projection has been achieved by taking into account the mobile margins of the breast. By elevating the inframammary fold, the skin of the upper breast can be relaxed and more breast tissue can be brought into the field of view. If the pectoralis major muscle is relaxed, it will project into the field of view on the craniocaudal view on approximately 30% of images (6).

The sternalis muscle is a supernumerary muscle located in the anterior thoracic region, running parallel to the sternum. Muscle

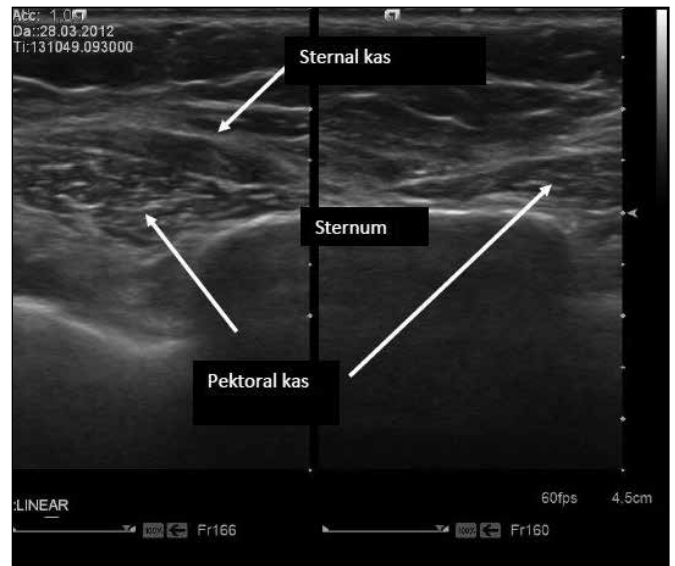


Figure 2. Transverse view over the sternum. Over the right pectoralis major muscle, ovoid, well-formed hypoechoic sternal muscle is seen. A hyperechoic fascia was easily delineated.

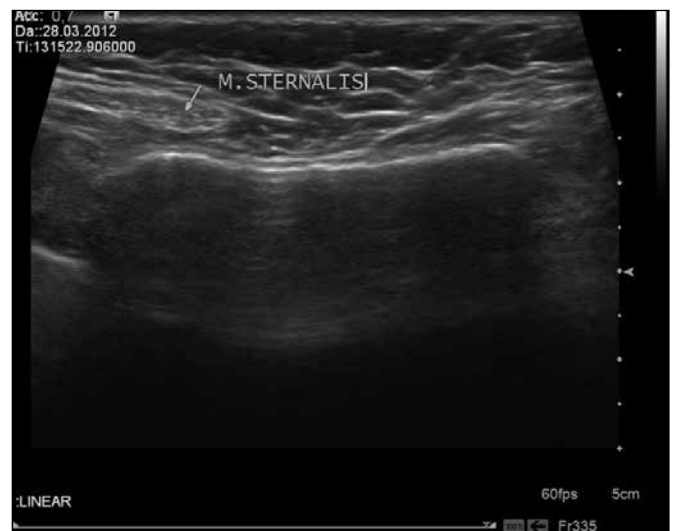

Figure 3. More inferior view of figure 2.

fibres arise from the sheath of the rectus abdominis muscle or adjacent structures and terminate upon the pectoralis fascia, upper sternum, costal cartilages, the sternum, or the medial heads of the sternocleidomastoid muscle (7, 8). The sternalis muscle can be either a few short fibres or a well-formed muscle, and may be unilateral or bilateral (7, 9). This variant was seen unilaterally and in the right breast in our case. When deep parts of the breast are visualized and high-quality images are obtained, the sternalis muscle may be seen in CC projections. It was first shown on mammography by Bradley et al. (5), who described it in six women. Four of those women were seen during screening and diagnostic mammographic imaging of 32.000 women (0.01%). Different anatomical studies have reported the prevalence of the sternalis muscle to be 1,9–23,5% (4). Its incidence was described as 6.2% in a study that examined multidetector computed tomography (CT) scans of

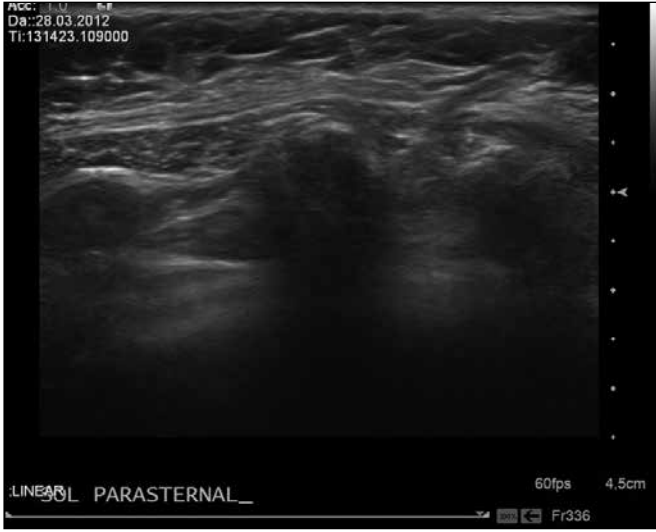

Figure 4. The sternal muscle seen in the longitudinal plane.

the chest in 1.387 adult patients (10). The sternalis muscle is usually seen as a small, asymmetric opacity at the medial posterior edge of the breast on mammogram CC views and can simulate breast pathology (11, 12). The muscle is isodense with fibroglandular densities and can be seen with varying diameters, shapes and contours on mammograms (13). The obtuse angle at the chest wall is typical of a muscular structure, and it is usually surrounded by fat (14). Significantly, it could not be detected in all follow-up images, and may appear larger or smaller on follow-up mammograms due to the distinct pulling of the breast during positioning. When a density suggesting the sternalis muscle is seen on a mammogram, it should be investigated with US like all other asymmetric opacities and mass-like densities with irregular or spiculated margins.

References

1. Fletcher SW, Black W, Harris R, Rimer BK, Shapiro S. Report of the International Workshop on Screening for Breast Cancer. *J Natl Cancer Inst* 1993; 85: 1644-56. (PMID: 8105098) [CrossRef]
2. Rosen PP, Groshen S, Saigo PE, Kinne DW, Hellman S. A long-term follow-up study of survival in stage I (T1N0M0) and stage II (T1N1M0) breast carcinoma. *J Clin Oncol* 1989; 7: 355-66. (PMID: 2918331)
3. Tabar L, Fagerberg G, Day N, Duffy SW, Kitchin RM. Breast cancer treatment and natural history: new insights from results of screening. *Lancet* 1992; 339: 412-4. (PMID: 1346670) [CrossRef]
4. Jeleu L, Georgiev G, Surchev L. The sternalis muscle in the Bulgarian population: classification of sternales. *J Anat* 2001; 199: 359-63. (PMID: 11554516) [CrossRef]
5. Bradley FM, Hoover HC Jr, Hulka CA, Whitman GJ, McCarthy KA, Hall DA, et al. The sternalis muscle: an unusual normal finding seen on mammography. *AJR Am J Roentgenol* 1996; 166: 33-6. (PMID: 8571900) [CrossRef]

The diagnosis of a mass can be eliminated with US and physical examination. We agree with Demirpolat et al. (15) that the sternalis muscle should be classified as BI-RADS category II and investigation beyond mammography and US is not indicated when an opacity resembling the sternalis muscle is seen. However, CT or MRI may be performed when there is any doubt. In conclusion, the sternalis muscle is a very rare chest wall muscle variant. Although it may mimic a mass lesion in a CC projection, understanding how to identify the muscle may lead to a final diagnosis and prevent further unnecessary investigation.

Conflict of Interest

No conflict of interest was declared by the authors.

Peer-review: Externally peer-reviewed.

Author Contributions

Concept - E.A.Ö., F.Ö.S.; Design - E.A.Ö.; Supervision - E.A.Ö.; Funding - E.A.Ö.; Materials - E.A.Ö.; Data Collection and/or Processing - E.A.Ö.; Analysis and/or Interpretation - E.A.Ö.; Literature Review - E.A.Ö.; Writing - E.A.Ö.; Critical Review - E.A.Ö.; Other - E.A.Ö., F.Ö.S.

Çıkar Çatışması

Yazarlar herhangi bir çıkar çatışması bildirmemişlerdir.

Hakem değerlendirmesi: Dış bağımsız.

Yazar Katkıları

Fikir - E.A.Ö., F.Ö.S.; Tasarım - E.A.Ö.; Denetleme - E.A.Ö.; Kaynaklar - E.A.Ö.; Malzemeler - E.A.Ö.; Veri toplanması ve/veya işlemesi - E.A.Ö.; Analiz ve/veya yorum - E.A.Ö.; Literatür taraması - E.A.Ö.; Yazıyı yazan - E.A.Ö.; Eleştirel inceleme - E.A.Ö.; Diğer - E.A.Ö., F.Ö.S.

6. Eklund GW, Cardenosa G. The art of mammographic positioning. *Radiol Clin North Am* 1992; 30: 21-53. (PMID: 1732927)
7. Scott-Conner CE, Al-Jurf AS. The sternalis muscle. *Clin Anat* 2002; 15: 67-9. (PMID: 11835549) [CrossRef]
8. Arraez-Aybar LA, Sobrado-Perez J, Merida-Velasco JR. Left musculus sternalis. *Clin Anat* 2003; 16: 350-4. (PMID: 12794922) [CrossRef]
9. Das S, Paul S, Mandal AK. Anomalous musculoskeletal morphology of anterior chest wall: a case report. *Arch Med Sci* 2006; 2: 289-291.
10. Young Lee B, Young Byun J, Hee Kim H, Sook Kim H, Mee Cho S, Hoon Lee K, et al. The sternalis muscles: incidence and imaging findings on MDCT. *J Thorac Imaging* 2006; 21: 179-83. (PMID: 16915061) [CrossRef]
11. Stines J, Tristant H. The normal breast and its variations in mammography. *Eur J Radiol* 2005; 54: 26-36. (PMID: 15797291) [CrossRef]
12. Cawson JN, Papadopoulos T. Variants of sternal insertions of the pectoral muscle on mammography: a pictorial review. *Clin Radiol* 2002; 57: 442-8. (PMID: 12069458) [CrossRef]
13. Goktan C, Orguc S, Serter S, Ovali GY. Musculus sternalis: a normal but rare mammographic finding and magnetic resonance imaging demonstration. *Breast J* 2006; 12: 488-9. (PMID: 16958972) [CrossRef]
14. DeParades ES. Atlas of mammography. 3rd ed. Philadelphia: Lippincott, Williams & Wilkins, 2007; 8.
15. Demirpolat G, Oktay A, Bilgen I, İsayev H. Mammographic features of the sternalis muscle. *Diagn Interv Radiol* 2010; 16: 276-8. (PMID: 20700868)

Correspondence / Yazışma Adresi

Ersen Alp Özbacı
Phone : +90 (532) 318 31 69
E-mail : drersenalpozbalci@gmail.com