



Three Dimensional Modelling in the Optimisation of Chest Wall Resection and Reconstruction Following Metastatic Breast Cancer

Hanad Ahmed¹, Mansoor Khan², Aiman Alzetani¹

¹Department of Thoracic Surgery, University Hospital Southampton, Southampton, United Kingdom

²Department of Plastics and Reconstructive Surgery, University Hospital Southampton, Southampton, United Kingdom

ABSTRACT

Two-dimensional computed tomography scans no longer offer the level of detail that many surgeons desire for more accurate and precise surgical intervention. Computed tomography image reconstruction into three dimensional (3D) virtual models with interactive capability is providing an enhanced understanding of the patient's anatomy and pathology allowing the surgeon to create tailored intraoperative plans, minimizing complications and maximizing the intended therapeutic outcome. In this case report we demonstrate the use of 3D image reconstruction software in the management of a 36-year-old female with metastatic breast cancer affecting the chest wall.

Keywords: Bone metastasis, breast imaging, metastasis

Cite this article as: Ahmed H, Khan M, Alzetani A. Three Dimensional Modelling in the Optimisation of Chest Wall Resection and Reconstruction Following Metastatic Breast Cancer. Eur J Breast Health 2022; 18(3): 286-288

Key Points

- Three-dimensional interactive modelling can enhance precision in anterior chest wall resection and limit the extent of the post-procedural chest wall deformity. Its use as an adjunct to other pre-operative modalities should be considered to support targeted resection.

Introduction

The surgical management of breast cancer patients must often accommodate psychosocial issues, in addition to surgical challenges. This is because surgical resection can often leave patients with significant chest wall deformity, suboptimal function, and aesthetics. It is therefore essential to ensure resection is limited to therapeutic benefit. This can be achieved by mapping exact tissue margins, ensuring maximal preservation of tissue whilst minimizing the risk of tumour recurrence. 3D modelling supports this process by enhancing pre-operative planning by using existing conventional computed tomography (CT) images to create 3D virtual reconstructions.

These models can aid in localising the exact extent of the chest wall tumour, guiding intraoperative resection. We report the case of a 36-year-old female who underwent an anterior chest wall resection for recurrent breast cancer. We highlight the use of interactive 3D image reconstruction software in the surgical management of this patient.

Case Presentation

A 36-year-old female presented with metastatic relapse of her breast cancer. This was on the background of a grade 3, oestrogen receptor and HER-2 positive, right-sided breast carcinoma, previously treated with chemotherapy, mastectomy, axillary node clearance and chest wall radiotherapy, followed by a delayed deep inferior epigastric perforators (DIEP) flap reconstruction.

In addition to metastatic deposits in the sternum, the cancer was also contiguous with the medial aspect of the DIEP flap. A CT scan revealed lesions in both the sternum and right breast extending from the skin to the chest wall, illustrated in Figures 1a and b. An ultra-high definition (HD) fluorodeoxyglucose (FDG) positron-emission tomography (PET) scan confirmed localised disease with no distant metastatic disease,

illustrated in Figure 1c. The patients only symptoms were a palpable erythematous lesion below the skin.

Due to the age of the patient and the localised nature of recurrence, it was decided to offer a partial anterior chest wall resection and reconstruction.

Preoperative Planning

To limit resection to therapeutic benefit and minimize resection of the chest wall, virtual 3D planning was used. This used existing CT scans of the patient to reconstruct a virtual model, highlighting both the site of the tumours and the extent of the planned en-bloc resection site informing the subsequent reconstruction strategy. Figures 2a and b illustrate the model and the planned resection site and size.

Operation

A curvilinear incision was planned and made, encompassing the sternum and anterior chest wall medial to the right nipple (Figure 3a). This was followed by en-bloc excision (Figure 3b and c) of the medial aspect of the left clavicle and all left sided ribs at the articulating point with the sternum. The right sternal edge was disarticulated in a similar fashion, except ribs 3, 4 and 5 which were divided laterally beyond the mid-clavicular line to achieve adequate clearance, as per the pre-operative planning, illustrated in Figure 2.

The area was reconstruction with a prolene mesh sandwich containing gentamicin cement (Figure 3d). The extent and shape of this was as per the planned pre-operative model. To complete reconstruction, a

left latissimus dorsi myocutaneous flap was raised and moved to the midline subpectoral plane (Figure 3e and f).

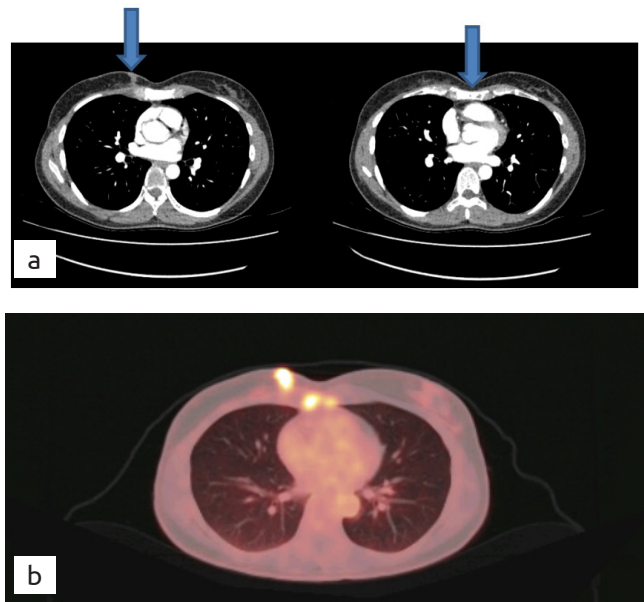


Figure 1. (a) Right breast nodule measuring 17x7 mm extending from the skin to the chest wall. (b) Extensive sclerotic lesions within the sternum. (c) PET scan showing multifocal hypermetabolic metastases within the right chest wall, right breast, and sternum

PET: positron emission tomography

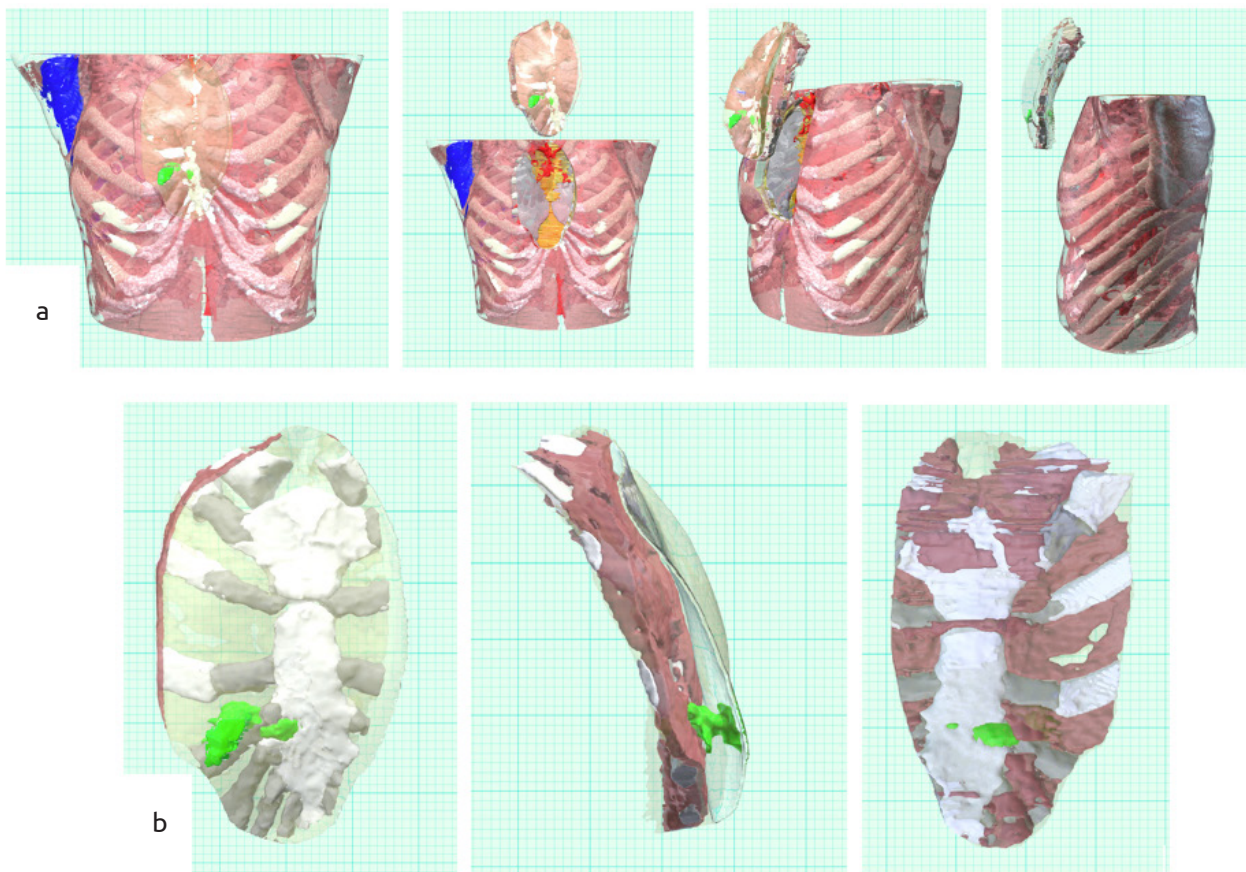


Figure 2. (a) 3D view of the chest wall, tumour (green) and planned resection site. (b) 3D view of the front, side and back of the planned resection site with tumour (green) *in situ*

3D: three dimensional

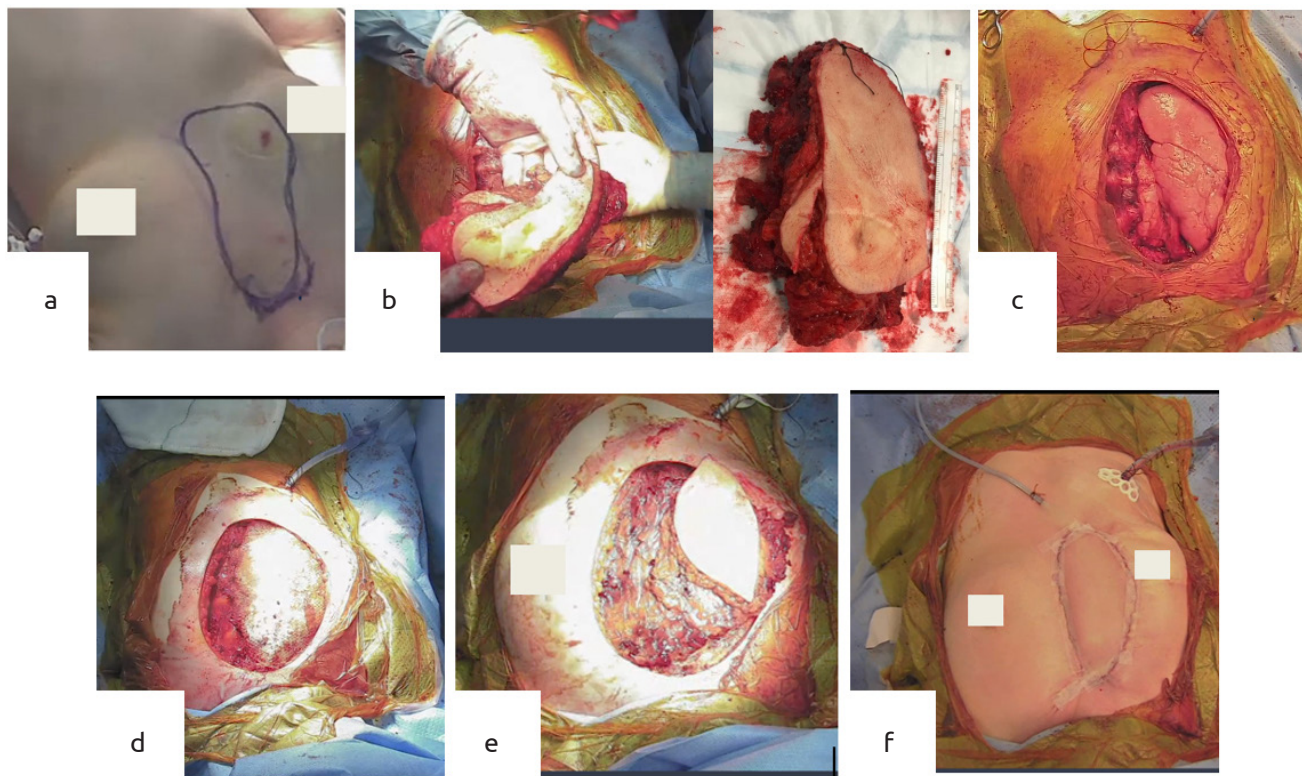


Figure 3. (a) Planned excision site. (b) Extraction of anterior chest wall encompassing tumour site. (c) Post chest wall resection with right lung exposed. (d) Gentamicin cement sandwiched between a prolene mesh filling defect site (e) Left latissimus dorsi myocutaneous flap raised and moved to midline subpectoral plane. (f) Completion of resection and reconstruction

The patient’s post-operative recovery was uneventful with a healthy wound showing no evidence of collections, or infection. She was subsequently referred to the plastics and reconstructive team to begin her right breast reconstruction.

Discussion and Conclusion

Preoperative 3D modelling has a wide range of possible applications in thoracic surgery, ranging from the planning and localization of lesions and anatomical structures in lobectomy or segmentectomy to the evaluation of thoracic anatomical deformities in children (1, 2).

In this case report we demonstrated its use in oncological anterior chest wall resection and reconstruction. The patient’s CT scan images were reconstructed by medical technology company Axial 3D. In addition to the 3D images, we were able to insert our desired margins for resection which allowed for the creation of virtual interactive models pre- and post-resection, which can be found here <https://sketchfab.com/3d-models/p02332-sketchfab-2f311f9284e242be8baf87836f69aeb5> and <https://sketchfab.com/3d-models/p02332-resection-02adfbf94d7541f293c88449a8dc5ca9>. This allowed us to limit the resection area to maximize therapeutic benefit and minimise chest wall deformity.

Our experience with the 3D modelling software highlighted the potential for us to go a step further in future resections by utilising the 3D models to create 3D printed prosthetics for more precise filling of the defect site.

In conclusion, 3D interactive modelling can enhance precision in anterior chest wall resection and limit the extent of the post-procedural chest wall deformity. Its use as an adjunct to other pre-operative modalities should be considered to support targeted resection.

Informed Consent: It was obtained.

Peer-review: Externally peer-reviewed.

Authorship Contributions

Concept: M.K., A.A.; Design: M.K., A.A.; Supervision: A.A.; Data Collection and/or Processing: H.A.; Literature Search: H.A.; Writing: H.A.; Critical Review: H.A., M.K., A.A.

Conflict of Interest: No conflict of interest was declared by the authors.

Financial Disclosure: The authors declared that this study received no financial support.

References

1. Heuts S, Sardari Nia P, Maessen JG. Preoperative planning of thoracic surgery with use of three-dimensional reconstruction, rapid prototyping, simulation and virtual navigation. *J Vis Surg* 2016; 2: 77. [\[Crossref\]](#)
2. Calloway EH, Chhotani AN, Lee YZ, Phillips JD. Three-dimensional computed tomography for evaluation and management of children with complex chest wall anomalies: useful information or just pretty pictures? *J Pediatr Surg*. 2011; 46: 640-647. (PMID: 21496531) [\[Crossref\]](#)